

Physical Examination of the Liver

C. David Naylor, MD, DPhil, FRCPC

CLINICAL SCENARIO

The patient in your examining room is new to the practice. He is 52 years old, emigrated from Southeast Asia about 10 years ago, and has no specific complaints except fatigue. On examination you find little of note except that his liver edge is firm, easily felt, and extends about 6 cm below the costal margin across much of the right upper quadrant. The span, by light percussion, is 17 or 18 cm. Should you be concerned? What does the research literature tell us about the meaning of these findings?

Ideally, the clinical meaning of physical examination findings should be established in research studies that account for the overall context, including other signs and details from the medical history. This approach is difficult in liver disease, because the physical manifestations of hepatic dysfunction are protean and many multisystem diseases affect the liver. Our focus, therefore, is on physical examination of the liver itself. This means, however, that we implicitly depend on the clinician's ability to make a baseline estimate of the likelihood of liver disease on the basis of the history and/or other physical findings.

Although many maneuvers recommended in liver examination are unproven, there is reasonable evidence that the presence or absence of hepatomegaly can be determined with moderate accuracy on physical examination. Descriptive studies suggest that other qualitative findings may help in clinical

assessment of patients with possible liver disease. Liver examination, like most physical diagnosis maneuvers, is not dissimilar to a screening test; it may support or refute hypotheses generated by the history, and generate further hypotheses itself, allowing more selective use of imaging techniques and laboratory tests as tools to confirm the suspected diagnoses.¹

TOPOGRAPHY

Situated intraperitoneally in the right upper quadrant, the liver seldom extends more than 5 to 6 cm across the midline into the left upper quadrant. The upper surface is convex and nestles under the diaphragm typically at the level of the fifth or sixth anterior rib in quiet respiration. The lower surface tends to be concave, with the gallbladder in it. Although the fundus of the gallbladder may project below and anteriorly to the lower liver edge, it is not felt in healthy persons.

The bulk of the liver sits posteriorly where it cannot be assessed from behind because of intervening retroperitoneal contents, ribs, and lumbar musculature. Anteriorly, the liver sits partly above the costal margin, with ribs and lung supervening, and partly below it. The portion extending below or inferior to the costal margin varies and typically runs parallel to the costal margin. However, physicians working in modern imaging departments, like generations of surgeons and anatomists before them, can attest to the degree of variability in the shape of the organ, including the extent to which the lower edge parallels the costal margin and the degree of extension beyond the midline into the left upper quadrant (Fig 1). To some extent, the vertical liver span (ie, the linear dis-

tance from the top of the liver dome down to the lower edge) is a function of where in the right hypochondrium the liver edge is palpated or percussed (Figs 1 and 2). The falciform ligament joins the midanterior surface of the liver to the diaphragm and anterior abdominal wall. With respiration, diaphragmatic contraction drives the liver downward, and the anterior surface of the organ rotates slightly to the right. In quiet inspiration and expiration, the excursion is approximately 2 to 3 cm.

A SUGGESTED APPROACH TO LIVER EXAMINATION

We assume that, as part of the general abdominal examination, you have already inspected the abdomen, including the right upper quadrant, looking for obvious irregularities or deformities. Then, in adults without a history or physical findings suggestive of potential liver disease, palpate for the lower liver edge. Start with gentle pressure in the right lower quadrant; ask the patient to breathe in gently and slowly to bring the liver edge down to the examining fingertips. At each exhalation, move the fingers up about 2 cm. If the edge is not felt, no further examination is suggested.

If the edge is felt, confirm that you are palpating roughly in the middle of the right portion of the abdomen, ie, corresponding to the midthoracic line or so-called midclavicular line (MCL). Mark the lower edge. Then, in the same approximate plane, percuss down from

From the Clinical Epidemiology Unit and the Division of General Internal Medicine, Sunnybrook Health Science Centre, Toronto, Ontario, and the Departments of Medicine and Surgery and the Graduate Department of Community Health, University of Toronto (Ontario). Reprints not available.

The Rational Clinical Examination section editors: David L. Simel, MD, MHS, Durham Veterans Affairs Medical Center and Duke University Medical Center, Durham, NC; Drummond Rennie, MD, Deputy Editor (West), JAMA.

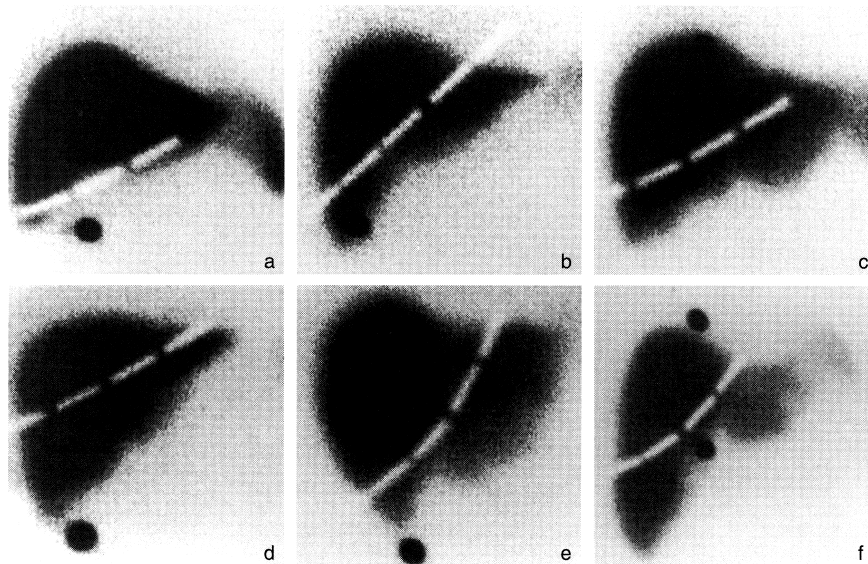


Fig 1.—Radioisotope scans of the liver showing variability in organ shape. Note the costal margin markers as white broken lines and the other two dark point markers for research purposes; respiratory excursion blurs and expands the point markers—a limitation on the precision of any study done with reference to scintigraphic standards. Images a through d show variation in alignment with the costal margin; images e and f show, respectively, prominence of the left (caudate) and right (pyramidal) lobes.

about the level of the third rib, with the pleximeter finger (the finger that you strike with the percussing finger) laid horizontally. Typical lung field resonance will be heard. Move one rib space at a time until the tone changes because of the interposition of the dome of the liver behind the air-filled lung. There will be a gradation with increasing dullness as you move caudally and the volume of the air-filled lung overlying the liver is diminished (Fig 3).

To confirm increased dullness, spread two or three pleximeter fingers over adjacent rib spaces and percuss quickly a number of times from greater to lesser resonance. If doubts persist, have the patient take a deeper breath and hold it; then percuss to confirm an unequivocal increase in resonance at that rib space. Determination of a level for the upper edge of liver dullness is sometimes helped by placing the middle finger over the likely level for initial tone change and laying the second and ring fingers on adjacent rib spaces. Again, percuss back and forth. The percussion tone over the fourth or ring (ie, top) finger should be resonant; the second or index finger, unequivocally dull; and the third finger, in between.

Try to ensure that the lower and upper borders are marked either in quiet respiration or, if deep breaths are taken, in the same phase of respiration.

In instances during which you have other evidence to suggest liver disease, but the liver edge was not palpable, attempt to locate the lower edge by gentle percussion in the right lower quadrant, following the plane of the MCL and again

working from resonance to dullness. Tricks similar to these (eg, multiple pleximeter fingers and manipulating level of dullness with changes in depth of respiration) may help confirm the finding. If there is no definite tone change up to the costal margin—a not uncommon finding—end the attempt to define liver size.

Determination of vertical liver span in the MCL can be done two ways. We recommend gentle percussion for locating the upper liver border and palpation or gentle percussion to locate the lower border. An alternative is to use firm percussion, deliberately ignoring whether or not the lower edge is palpable.

Liver size correlates with body size, and liver shape correlates with habitus. Liver span is greater in men than women and in tall vs short persons. However, as a rough guide, an MCL span of less than 12 to 13 cm with gentle percussion alone or gentle percussion combined with palpation makes hepatomegaly very unlikely. Ranges of normal have been established for firm percussion (Table 1) but will vary among clinicians depending on percussion techniques. Enlargement suggested by percussive span alone is weaker evidence for hepatomegaly than span based on palpation of the lower liver edge.

Apart perhaps from the situation of fulminant hepatic failure, observing reduction in liver span is of limited usefulness since many other features of chronic liver failure will be present in situations in which reduction in parenchymal mass has occurred.

When the liver edge is palpable, trac-

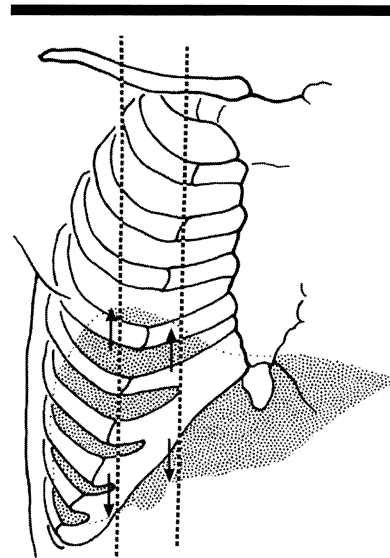


Fig 2.—Variation in liver span according to the vertical plane of examination. Since there is variability in where clinicians determine the midclavicular line to be, the inevitable consequence is that liver span may also vary, even if multiple observers are perfectly accurate in measuring it.

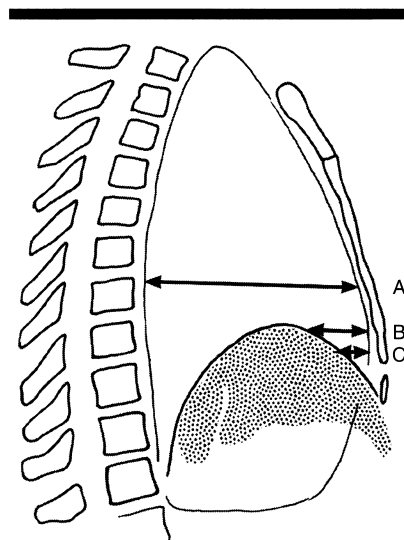


Fig 3.—Percussive resonance varies with the thickness of interposed air-filled lung tissue. The percussion note changes with decreasing resonance caudally as less air-filled lung tissue is interposed between the liver and ribs. However, the site of a change from obvious resonance over the lung (point A) to less resonance (points B and C) may be difficult to judge.

ing the edge and defining its characteristics qualitatively is recommended primarily in persons who are strongly suspected of having liver disease. Auscultation is seldom helpful. Once you have a high index of suspicion about liver disease, biochemical tests and biopsy are the main events; the more esoteric findings on physical examination

Table 1.—Normal Liver Span in the Midclavicular Line (MCL) and the Midsternal Line (MSL), as Determined With Heavy Percussion Alone³⁷

Height, cm	MCL, cm		MSL, cm	
	Male	Female	Male	Female
150	8.25	6	6	4
157.5	9	6.75	6.5	4
165	9.75	7.5	7	5
172.5	10.25	8	7.5	...
180	11	8.75	8	...
187.5	11.75	9.5	8.5	...

*Ellipses indicate data not available.

Table 2.—Potential but Unproven Means to Differentiate Venous Hums and Arterial Bruits

Feature	Venous Hum	Arterial Bruit
Pitch	Lower	Higher
Volume	Soft	May be loud
Timing	Continuous	Systolic
		Systolic and diastolic
Systolic accentuation	Yes	Yes
Localized	No	Yes
Change with position	Yes	Sometimes*
Change with inspiration	Louder	May decrease
Stethoscope pressure	Diminishes	Unchanged

*Although positional change in arterial bruits would not be expected in an arterial bruit caused by tumor vascularity per se, positional change may occur if a bruit is due to pressure on the abdominal aorta from the enlarged left lobe of the liver.^{4,5,9}

become a sideshow for impressing referring physicians or trainees.

EVIDENTIARY BASIS FOR THE APPROACH

Inspection

Visualization of infracostal extension of the liver is occasionally possible when malnutrition and/or cachexia thin out the overlying tissues or when there is massive hepatomegaly. No studies, to our knowledge, describe the yield from inspection of the liver outline in the abdomen, but clear-cut abnormalities should at least be specific thereby ruling in hepatomegaly and underlying disease.

Auscultation

Friction rubs may occur with primary and metastatic malignancies, after liver biopsies, with infective and inflammatory conditions, and with or without concomitant hepatomegaly. Rubs, though always abnormal, are rare and nonspecific; even with careful examination of patients with liver tumors, no more than 10% of patients have a rub.^{2,4}

A detailed review of abdominal auscultation is provided by Sapira,⁵ including bruits and hums occurring in and around the right upper quadrant. Considerable time can be spent on auscultation, but there is no evidence that these

Table 3.—Probability of Hepatomegaly if a Liver Is Palpable or Not and Related Likelihood Ratios

Liver Palpability	Hepatomegaly		Likelihood Ratio (LR)*
	Yes	No	
Peternel et al ^{1†}			
Yes	12	12	LR+=1.7 (95% CI, 1.0-2.8)
No	4	15	LR-=0.45 (95% CI, 0.18-1.1)
Rosenfield et al ^{2‡}			
Yes	24	28	LR+=1.4 (95% CI, 1.0-2.1)
No	13	35	LR-=0.63 (95% CI, 0.39-1.0)
Walk ^{4§}			
Yes	195	263	LR+=2.6 (95% CI, 2.3-3.0)
No	95	768	LR-=0.44 (95% CI, 0.37-0.52)
Pooled			
Yes	231	303	LR+=2.5 (95% CI, 2.2-2.8)
No	112	818	LR-=0.45 (95% CI, 0.38-0.52)

*Confidence intervals (CIs) on LRs were determined using the method of Simel et al.⁴⁴ Plus sign indicates positive LR; minus sign, negative LR.

†Scintigraphic span of 16.5 cm or more; this reflects an arbitrary interpretation based on the bigger-than-usual span among clinically normal persons reported by Peternel et al.¹⁴

‡Scintigraphic midclavicular line span of 15.5 cm or more.

§Volume greater than 1100 mL/m², where volume of 900 mL/m² usually signifies enlargement.

findings are helpful in routine examination. Features reputed to help separate bruits of arterial and venous sources are noted in Table 2. Venous hums occur in portal venous hypertension of any cause. The hum, a low-pitched murmur with systolic and diastolic components, arises from communication between the umbilical or paraumbilical veins and abdominal wall veins. The responses of venous hums to Valsalva's maneuver, splenic pressure, or ingestion of meals are inconsistent.^{6,7} Other causes of true continuous murmurs, such as arteriovenous fistula in the splanchnic circulation or hepatic hemangioma, are uncommon, and arterial bruits rarely have such lengthy diastolic spillover that they sound continuous.^{4,8}

Arterial bruits over the liver or in the epigastrium have been described with most liver tumors, as well as alcoholic hepatitis.^{2,4,8-11} However, among patients with liver disease in general (eg, a convenience sample of cirrhosis, alcoholic hepatitis, and malignancy), the prevalence of bruits has been reported at less than 3%.⁸ Both clinically⁹ and with phonoangiographic enhancement,⁸ the murmurs associated with alcoholic hepatitis and malignancy cannot be distinguished from one another, although the former resolve if and when the condition improves. The prevalence of clinically audible bruits in patients with confirmed liver cancer varies from 10%¹¹ to as much as 56%.¹² Kingston et al¹³ reported a diastolic component to most bruits heard in their patients with hepatoma. About 1% to 2% of unselected patients on a general medical service will have abdominal bruits of some kind,⁴ and the ability of clinicians to distinguish hepatic from other arterial bruits has never been assessed.

Auscultation over the liver should be considered only when history and other

physical findings are suggestive of hepatic disease; even then, the findings should be interpreted cautiously.

A PALPABLE LIVER EDGE: WHAT DOES IT MEAN?

Cirrhosis or infiltrative disorders increase the firmness of the liver edge and the likelihood of its being felt independent of effect on organ size.¹⁴ Among gastroenterologists, agreement on the presence of a palpable liver edge is about 50% greater than expected by chance alone.¹⁵ More interobserver disagreement would be expected in ordinary practice.

There is a paucity of data on the prevalence of palpable livers in the general population. One study¹⁶ has reported data on palpability of the liver among 1000 military personnel (717 men and 283 women) undergoing routine examination; 852 subjects were 40 years of age or younger. Palmer, the author and sole examiner, excluded any persons in whom liver disease was suspected or who were difficult to examine. In 57% of subjects, the liver either was not palpable in the right upper quadrant or was felt just at the costal margin. An additional 28% descended only 1 to 2 cm below the costal margin. Findings were similar for both sexes. The proportion of palpable livers was inflated by two factors. First, all subjects were examined in deep-held inspiration. Second, as Palmer himself cautioned, "there is no question but that many of the potentially palpable livers would have been overlooked if this had not been a specially directed study."

Ability to palpate the liver is not closely correlated with liver size in studies using reference standards such as scintigraphy or ultrasonography.¹⁷⁻²⁰ (Although many published studies use scintigraphy as a reference standard, it does

Table 4.—Match of Clinically Measured Midclavicular Line (MCL) Span and Imaged Span

Authors and Procedure	No. (%) of Patients With MCL Proportion Within 2 cm/ No. of Total Patients	No. of Observers	Imaging Method
Sullivan et al ¹⁹			
Scratch test	15/36 (42)		
Percussion alone	19/47 (40)	1	Scintigraphy, MCL not matched
Palpation alone (where applicable)	17/32 (53)		
Fuller et al ³⁴			
Palpation and or percussion and scratch test	31/40 (78)		
Palpation and/or percussion alone	16/36 (44)	3 or 4	Ultrasound, MCL matched*
Peternel et al ¹⁴			
Percussion and palpation	18/43 (42)	2 or 3†	Scintiscan, MCL not matched
Naylor et al ³³			
Percussion and/or palpation			
Observer 1	20/39 (51)	1	Scintiscan, MCL matched
Observer 2	13/34 (38)	1	Scintiscan, MCL matched

*Span from costal margin only.
†Mean MCL span used when observers differed.

have the drawback of motion artifact in conventional applications.) Patients undergoing liver scintiscan are preselected, and a high proportion of palpable livers might be expected. However, studies from nuclear medicine departments show that although the overwhelming majority of patients scanned have some infracostal extension of the liver, less than half of these patients had palpable livers.^{14,18-21} In one study, Rosenfield et al²² chose 100 scintiscans at random and compared the findings with the clinical records. Among patients without definite evidence for liver disease in the medical records, mean scintigraphic vertical span in the right MCL was similar among those with palpable (12.9 cm) and nonpalpable organs (12.5 cm), as were the proportions in each category (45% vs 55%). Overall, the chance that a patient with a palpable liver also had liver disease were 63% (36 of 57 patients; 95% CI, 49% to 76%), but the chances of a palpable liver meeting scintigraphic criteria for enlargement were only 46% (24 of 52 patients; 95% CI, 32% to 61%). Studies^{14,22,23} on palpability and hepatomegaly are summarized in Table 3. This distinction between abnormal and enlarged livers is a recurrent problem because livers may be abnormal yet not enlarged.

What of the converse proposition, ie, that a nonpalpable liver is not enlarged? Since normal livers usually extend below the costal margin yet may not be palpable, this proposition rests on an assumption that enlarged livers will be diseased, abnormally hard, and therefore much more easily felt. As summarized in Table 3, a nonpalpable liver does reduce the probability of hepatomegaly, even though a palpable organ has less than a 50% chance of being enlarged. These figures are influenced by the pooled prevalence of hepatomegaly, 23%

in these studies. As a prevalence-free parameter, we can report that the pooled likelihood ratio²⁴ (LR) for hepatomegaly, given a palpable liver (LR+), is 2.5. The LR in the absence of palpable hepatomegaly (LR-) for the presence of an enlarged liver detected by scanning is 0.45. However, there will likely be a workup bias in these figures as a result of preferential referral of patients with palpable livers for scintigraphy. This bias would arguably lead to a slight overestimate of sensitivity and still larger underestimate of specificity. If specificity were higher, the LR+ would be stronger. In any event, an LR approach is most useful if you know the prior odds of hepatomegaly for representative cohorts of patients with various diseases—a set of numbers that are currently unknown and should be the subject of research in the future.

In sum, a palpable liver is not necessarily enlarged or diseased but does increase the likelihood of hepatomegaly. The vertical liver span and overall clinical context must also be considered. Conversely, a nonpalpable liver edge does not rule out hepatomegaly but does reduce its likelihood. This is particularly relevant in those settings of low prior probability of liver disease where further examination is likely to have little yield if the liver cannot be felt.

WHAT ELSE CAN BE LEARNED FROM PALPATION?

Da Costa²⁵ wrote 70 years ago, “Tactile sense decides the questions of hepatic tenderness, pulsation, friction, and thrills . . . and determines the consistency and the contour of its anterior and lower surfaces.” However, there are few data on the reliability and accuracy of these qualitative judgments about liver edge characteristics.

A pulsatile liver edge is well docu-

mented in tricuspid valvular disease.²⁶⁻²⁸ Although this sign may be present clinically in the majority of cases,²⁹ no modern studies adequately document the frequency of the association and its relationship to differing degrees of tricuspid valvular dysfunction. Unequivocal pulsatile hepatomegaly is also reported in 35 of 55 consecutive patients (64%; 95% CI, 50% to 76%) with confirmed constrictive pericarditis accumulated in two separate case series.^{30,31} The low false-negative rates give this sign some potential value in a setting where constrictive pericarditis is already suspected. Unfortunately, as Osler³² noted a century ago, there is a need to distinguish between an expansile liver edge and transmitted aortic or right ventricular impulses that are commonly present. There are no data on examination maneuvers to make such a distinction, although inspiratory increase in the magnitude of the pulsation has been reported anecdotally with tricuspid insufficiency.²⁶ Detection of differential timing of hepatic pulsations has been described (eg, A vs V waves) but is rare and doubtless difficult to pinpoint.²⁷

Palpation for an expansile liver edge should be limited to cases of suspected tricuspid valve disease or constrictive pericarditis.

The other qualitative parameters are consistency, nodularity, and tenderness of a palpable liver edge. Among multiple expert observers examining variously alcoholic or jaundiced patients, κ statistics for chance-corrected agreement were 11% for abnormal consistency of a palpable liver edge¹⁵ and 26%¹⁵ or 29%³³ for presence of nodularity. Only agreement on tenderness of the liver edge was within a useful range at 49%.³³

Palpation to describe the liver edge qualitatively or to detect isolated enlargement of the left (caudate) lobe of the liver should therefore be considered primarily if there is other evidence of organ disease or concern about liver tumor and even then, is optional.

ASSESSING VERTICAL LIVER SPAN

Unequivocal reduction in liver size should be detectable in fulminant hepatic failure. However, no evidence was located to support the common belief that a substantial proportion of persons with chronic cirrhosis have detectably small livers by physical examination. The focus herein is accordingly on hepatomegaly.

Since half of all palpable livers are not enlarged, measurement of vertical liver span in some plane is required. The usual reference point is the MCL. However, unless care is taken in examination, the MCL can be “a wandering landmark,”

with documented interobserver variation as much as 10 cm.³⁴ Variation in the MCL will inevitably lead to imprecision in liver span assessments (Fig 2). Note also that vertical span could only be an accurate predictor of liver mass if the organ were more or less cuboid rather than irregular.

Palpation should, in theory, be the most reliable and accurate method of locating the lower border of the liver to measure organ span. Two studies^{12,33} report specialists' ability to agree on distance from the costal margin to a palpable liver edge, an approach that overstates accuracy by eliminating the largest source of error—location of the upper border of the liver.^{14,19,35} Meyhoff et al¹² further controlled interobserver disagreement by having all measurements made at a predetermined MCL. Mean maximum interobserver difference about distance from the costal margin was 6.1 cm (SD, 2.7 cm) in the MCL. Intraobserver variation was smaller, with differences not greater than 2 cm in 60% to 80% of MCL measurements. There was no clear relationship to liver size, a finding that underscores the need to measure span from the upper border of the liver not the costal margin. Theodossi et al³³ performed a similar experiment without marking the MCL. The intraclass correlation coefficient was 0.66, analogous to a weighted κ of more than 60%. However, agreement beyond chance on whether the liver was truly enlarged was only 30%.

What are the alternatives to localizing the lower liver edge by palpation? The scratch test is performed by placing the diaphragm of the stethoscope at the xiphisternum or over the liver just above the costal margin in the MCL. Starting low in the abdomen, a finger is moved up the abdomen scratching gently. The intensity becomes greatly enhanced once the finger is over the lower border of the liver.³⁶ The other major alternative is percussion.

Comparative studies are summarized in Table 4.^{19,36} Two caveats are in order. Both studies involved limited numbers of observers and patients. As well, the overall accuracy in the report by Fuller et al³⁶ is greatly exaggerated on two scores. First, the ultrasonographic measurement was made in a plane defined by the observers. In actual practice, the MCL of the clinical observer varies from that of the scintigrapher or ultrasonographer,^{34,35} a situation that was applicable for the patients examined by Sullivan et al.¹⁹ Second, Fuller et al took their measurements from the costal margin.

The scratch test may be a useful adjunct to percussion or palpation in lo-

cating the lower edge of the liver. However, further studies are needed before it can be recommended for routine use.

Also shown in Table 4 are the results of other studies in which the authors used percussion and/or palpation to locate the lower liver edge. Excluded is one outlying study in which 100% of measurements were accurate within 2 cm of scintigraphic MCL span and exact agreement at the 0.1-cm level is claimed for several observations.¹⁷ We also exclude a study using direct percussion without a pleximeter finger³⁷; this study related mean clinical liver span to ultrasonographic span, but lacked measures of either case-by-case absolute span discrepancies or categorical agreement on organ normalcy.

Once span has been determined, clinicians must still decide whether the liver is enlarged or not. Blendis et al³⁸ reported that among 28 patients with blood dyscrasias or liver diseases examined by four observers, three of four observers agreed in 93% of cases about the presence or absence of hepatic enlargement, but the data do not permit a κ correction. Theodossi et al,³³ with five observers and a structured history and physical examination on 20 jaundiced patients, reported a κ for presence or absence of hepatomegaly of 30%. Moreover, agreement among the qualitative judgments of clinicians and an external reference standard is modest. For example, Blendis et al³⁸ found that in the cases in which at least three clinicians agreed on hepatomegaly, concordant assessments of radiological liver surface area were found in only 48% of cases. Halpern et al²⁰ compared judgments recorded in medical charts with a convenience sample of 214 scintigraphic images with 16 cm as the cut point. Accuracy was 66%, slightly higher than in the Blendis study. However, when corrected for agreement expected on the basis of chance alone, the resulting κ statistic was only 32%. Naylor et al³⁵ used 15 cm as a cut point for scintigraphic hepatomegaly and, with two observers, found that the accuracy of clinical examination ranged from 67% to 82%, depending on the observer and choice of clinical threshold value for determining the presence of hepatomegaly. Correcting for chance agreement, the κ statistics ranged from 28% to 55%. Overall, it appears that combinations of palpation and percussion yield modest accuracy greater than expected by chance alone in determining whether the liver is enlarged or not.

Castell et al³⁹ suggested measuring span by percussion alone. They examined 116 healthy subjects to establish a range of normal for percussive span in

the MCL and midsternal line. Since the goal was to establish a clinical range of normal, there was no reason to validate the measurements against a reference standard. Percussive span correlated positively with height and differed between males and females as would be expected from autopsy studies (Table 1). Formulas to predict span were derived that incorporated height and weight. Midclavicular line liver dullness for males (cm) = $\{[0.032 \times \text{weight (lb)}] + [0.18 \times \text{height (in)}]\} - 7.86$. Midclavicular line liver dullness for females (cm) = $\{[0.027 \times \text{weight (lb)}] + [0.22 \times \text{height (in)}]\} - 10.75$.³⁹

The advantages of percussion alone are that observers may not agree on the presence of a palpable liver, and palpable livers will often be felt below the point where the percussion note changes. The latter occurs because the thin lower liver edge may not cause dullness. Thus, since not all livers are palpable, you must rely on palpation in a variable proportion of subjects, and these subjects will tend to have somewhat larger liver spans. However, clinical MCL span compared with technetium scintigraphic span is less accurate when the lower border is nonpalpable,^{14,19} and errors are always greatest in the upper border that can only be approached by percussion.^{14,19,35} It therefore seems counterintuitive to propose examining liver span by percussion alone. Also, the forcefulness of percussion greatly modifies the measured span.^{19,39,40} Use of percussive span therefore demands that each observer double-check his or her own range of normal against the established norms to ensure that strength of percussion is not a confounder.

Another group used the percussive span technique⁴¹ to examine 46 patients with liver disease. There was significant disagreement among six examining clinicians, presumably because of strength and plane of percussion. Interobserver agreement on the appraisal of the organ as "small," "normal," or "enlarged" was excellent only for massively enlarged livers. If moderately enlarged organs (ultrasound volumes between 2000 and 2700 mL) are included, the probability of any two randomly chosen observers agreeing on the presence of hepatomegaly was between 40% and 75%.

This limited performance is perhaps understandable since the concept of percussive span rests on the questionable assumption that it consistently underestimates liver span allowing for reliable demarcation of abnormally sized livers. Nonetheless, Castell et al³⁹ are the only group to establish a range of normal for clinical liver span that re-

flects the known variability of span with height, weight, and gender.

Use of percussion alone to determine span, independent of whether or where the lower liver edge is felt, remains feasible. However, clinicians should standardize their percussion technique and compare their typical findings in normal subjects to published normal ranges. Future research should evaluate the clinical utility of the percussive method as compared with methods using percussion and palpation, with and without the "scratch test."

PHYSICAL FINDINGS IN CONTEXT

In the foregoing studies, accuracy is generally defined against a single reference standard such as ultrasound or scintigraphy. This procedure contrasts with studies such as the one by Rosenfield et al²² in which measured span and palpability were compared with evidence in the clinical record for any liver disease. The latter study has the advantage of capturing the fact that although all truly enlarged livers are diseased, not all normal sized livers are free of disease.

A further problem with many studies is the extent of blinding. Some studies blind observers to all details of the patients' history and other physical findings. Others ask observers to perform a structured history and physical examination or set inclusion criteria (eg, jaundiced or alcoholic patients) that will affect clinicians' judgments. The nature and extent of confounding from this variable is unknown, but it seems probable that the extent of interobserver agreement, and even the match between clinical judgments and reference standards, will be affected by the amount of information available to the examiner.

Finally, few studies try to place liver findings in the overall context of clinical decision making. Sapira¹ has noted that clinical liver span assessments need not match closely ultrasonographic or scintigraphic measures, since the "clinical worth" of a sign is its potential contribution to clinical decision making. Of interest, Espinoza et al¹⁵ used stepwise discriminant analysis to assess the ability of a variety of physical findings to distinguish among 50 consecutive alcoholic patients presenting variously with cirrhosis, noncirrhotic alcoholic liver disease, or no clinical/biochemical evidence of liver disease. Three variables—spider nevi, splenomegaly, and abdominal wall collateral veins—appeared useful; liver examination findings were not significant contributors to the differential diagnostic exercise. Similarly, Theodossi et al^{42,43} examined the ability of a large array of symptoms and signs to differ-

entiate between medical and surgical causes of jaundice. They found that descent of the liver edge more than 2 cm below the costal margin was more common with surgical causes of jaundice ($P<.01$), but the independent contribution of this sign to the overall diagnostic process was unclear.

Both studies started with populations that had liver disease and determined whether physical diagnosis helped in categorizing the type of disease. Neither addresses whether the physical examination was helpful in deciding which patients had liver disease in the first place. Little is known about the real contribution of liver examination findings to the overall clinical diagnostic and management process. This topic should be a research priority.

WHAT CAN YOU DO TO GET BETTER AT EXAMINING THE LIVER?

No educational studies, to our knowledge, have tested methods to improve your accuracy and precision in examining the liver, but a few suggestions can be hazarded. First, once you are comfortable examining the liver, pursue the various shortcuts recommended herein. Early on, however, it is useful to check the liver span by percussion even in persons with a low probability of liver disease and a nonpalpable organ. This can help you begin to understand what your own range of normal is likely to be. Second, check your reliability by reexamining stable patients and comparing your follow-up assessment with your first impressions. Third, both tyros and experts should quantitatively and qualitatively benchmark their physical examinations of the liver against findings on nuclear examination or ultrasound. Try to determine how you are doing in assessing vertical liver span or extent of descent of the edge below the costal margin or in "calling" the presence of hepatomegaly. Fourth, consider the potential errors in locating the MCL. If sequential clinical span assessments are being made (eg, fulminant hepatic failure or treatment of hepatic metastases), it may help to record a reference plane such as 10 cm from the midline or, alternatively, where the lateral edge of the rectus abdominus crosses the costal margin.⁴⁴

THE BOTTOM LINE

Once historical data and other physical signs have been elicited, the additional value of a detailed physical examination of the liver remains uncertain. Moreover, just as diagnostic tests yield little at the extremes of prior probability, so also would you expect less yield from liver examination in persons who are not suspected of having liver

disease or who are obviously suffering from some hepatobiliary complaint.

A selective approach to physical examination of the liver is therefore suggested. Palpate to locate the lower liver border in the MCL in situations of low probability of liver disease. If the liver is not palpable, one can defensibly forgo any further examination in patients without reasons to suspect liver disease. Since, however, palpation of the abdomen is difficult in some subjects, light percussion remains an option to confirm lack of extension of the liver edge below the costal margin and/or guide further palpation. With a palpable lower edge, MCL span can be ascertained by light percussion of the upper border. A span of less than 12 to 13 cm reduces the probability of hepatomegaly. In persons with an impalpable liver and a high probability of liver disease, measuring span by percussion alone may also be worthwhile; tables of norms have been published, although these apply to moderate or heavy percussion methods. Palpation specifically to assess the quality of the liver edge is recommended only if there are signs of liver disease, including unequivocal hepatomegaly. Auscultation over the liver has a limited role in examination.

The author has learned from the comments of David L. Sackett, MD, and David L. Simel, MD, MHS, who offered constructive editorial advice, and from helpful hepatological colleagues in Toronto, namely, Jenny Heathcote, MD, and Laurence Blendis, MD. Joseph D. Sapira, MD, also shared his wisdom as a reviewer but frequently disagreed with what has been written here. These persons should share any credit and be spared any blame for errors or omissions.

References

1. Sapira JD. Why perform a routine history and physical examination? *South Med J*. 1989;82:364-365.
2. Zuidema PJ, Van der Meer C. Systolic liver murmurs in primary carcinoma of the liver. *Trop Geogr Med*. 1966;18:265-271.
3. Fenster LF, Klatskin G. Manifestations of metastatic tumors of the liver. *Am J Med*. 1961;31:238-248.
4. Sherman HI, Hardison JE. The importance of a coexistent hepatic rub and bruit. *JAMA*. 1979;241:1495.
5. Sapira JD. *The Art and Science of Bedside Diagnosis*. Baltimore, Md: Urban & Schwarzenberg; 1989:377-384.
6. Ramakrishnan T. Venous hum of the Cruveilhier-Baumgarten syndrome. *Arch Intern Med*. 1978;138:826.
7. Hardison JR. Venous hum of the Cruveilhier-Baumgarten syndrome. *Arch Intern Med*. 1977;137:1623-1624.
8. Zonerach S, Zonerach O. Diagnostic significance of abdominal arterial murmurs in liver and pancreatic disease: a photoarteriographic study. *Angiology*. 1971;22:197-205.
9. Clain D, Warnaby K, Sherlock S. Abdominal arterial murmurs in liver disease. *Lancet*. 1966;2:516-519.
10. Motoki T, Hayashi T, Katoh Y, Sakamoto T, Takeda T, Murao S. Hepatic bruits in liver tumours. *Lancet*. 1978;2:259.
11. Motoki T, Hayashi T, Katoh Y, Sakamoto T,

- Takeda T, Murao S. Hepatic bruits in malignant liver tumors. *Am J Gastroenterol*. 1979;71:582-586.
12. Meyhoff HH, Roder O, Andersen B. Palpatory estimation of liver size. *Acta Chir Scand*. 1979;145:479-481.
13. Kingston M, Ali MA, Lewall D. Hepatic tumors in Saudi Arabia: a practical approach to diagnosis. *Cancer*. 1985;55:1579-1585.
14. Peternel WW, Schaefer JW, Schiff L. Clinical evaluation of size and hepatic scintiscan. *Am J Dig Dis*. 1966;11:346-350.
15. Espinoza P, Ducot B, Pelletier G, et al. Inter-observer agreement in the physical diagnosis of alcoholic liver disease. *Dig Dis Sci*. 1987;32:244-247.
16. Palmer ED. Palpability of the liver edge in healthy adults. *US Armed Forces Med J*. 1958;9:1685-1690.
17. Naffalis J, Leevy CM. Clinical examination of liver size. *Am J Dig Dis*. 1963;8:236-243.
18. Ralphs DNL, Venn G, Kan O, Palmer JG, Cameron DE, Hobsley M. Is the undeniably palpable liver ever 'normal'? *Ann R Coll Surg Engl*. 1983;65:159-160.
19. Sullivan S, Krasner N, Williams R. The clinical estimation of liver size: a comparison of techniques and an analysis of the source of error. *BMJ*. 1976;2:1042-1043.
20. Halpern S, Coel M, Ashburn W, et al. Correlation of liver and spleen size: determinations by nuclear medicine studies and physical examination. *Arch Intern Med*. 1974;134:123-124.
21. Ariel IM, Briceno M. The disparity of the size of the liver as determined by physical examination and by hepatic gamma-scanning in 504 patients. *Med Pediatr Oncol*. 1976;2:69-73.
22. Rosenfield AT, Laufer I, Schneider PB. The significance of a palpable liver. *Am J Roentgenol Radiat Therapy Nucl Med*. 1974;122:313-317.
23. Walk L. Liver size and its post-mortem change. *Radiologe*. 1983;23:189-191.
24. Simel DL, Samsa GP, Marchar DB. Likelihood ratios with confidence: sample size estimation for diagnostic test studies. *J Clin Epidemiol*. 1991;44:763-770.
25. DaCosta JC Jr. *Principles and Practice of Physical Diagnosis*. 3rd ed. Philadelphia, Pa: WB Saunders Co; 1915:542.
26. Bokhari SI, DeSa'Neto A, Desser KB, Benchimol A. Inspiratory augmentation of hepatic pulsation in tricuspid insufficiency. *Chest*. 1979;76:89-90.
27. George DS, Marsh C, Leier CV. A-wave:liver. *Clin Cardiol*. 1988;11:349-350.
28. Pelteret RM, de Moor MM. Unusual cause of pulsatile liver: a case report. *S Afr Med J*. 1988;74:74-75.
29. Muller O, Shillingford J. Tricuspid incompetence. *Br Heart J*. 1954;16:195-207.
30. Bhatia ML, Tewari HL. Hepatic pulsations in constrictive pericarditis. *Indian Heart J*. 1974;26:165-170.
31. Manga P, Vythilingum S, Mitha AS. Pulsatile hepatomegaly in constrictive pericarditis. *Br Heart J*. 1984;52:465-467.
32. Osler W. *The Principles and Practice of Medicine*. New York, NY: Appleton and Co; 1893:428-456.
33. Theodossi A, Knill-Jones RP, Skene A, et al. Inter-observer variation of symptoms and signs in jaundice. *Liver*. 1981;1:21-32.
34. Naylor CD, McCormack DG, Sullivan SN. The midclavicular line: a wandering landmark. *Can Med Assoc J*. 1987;136:48-50.
35. Naylor CD, McCormack DG, Driedger AA, Craddock TD. Assessing liver size: clinical span versus scintigraphic span and tomographic volume. *Clin Invest Med*. 1988;11:C90, R573.
36. Fuller GN, Hargreaves MR, King DM. Scratch test in clinical examination of the liver. *Lancet*. 1988;2:181.
37. Skrainka B, Stahlhut J, Knight F, Holmes RA, Butt JH. Measuring liver span: bedside examination versus ultrasound and scintiscan. *J Clin Gastroenterol*. 1986;8:267-270.
38. Blendis LM, McNeilly WJ, Sheppard L, Williams R, Laws JW. Observer variation in the clinical and radiological assessment of hepatosplenomegaly. *BMJ*. 1970;1:727-730.
39. Castell DO, O'Brien KD, Muench H, Chalmers TC. Estimation of liver size by percussion in normal individuals. *Ann Intern Med*. 1969;70:1183-1189.
40. Sapira JD, Williamson DL. How big is the normal liver? *Arch Intern Med*. 1979;139:971-973.
41. Malchow-Moller A, Rasmussen SN, Jensen AM, Keilding N, Skovgaard LT, Juhl E. Clinical estimation of liver size. *Dan Med Bull*. 1984;31:63-67.
42. Theodossi A, Spigelhalter DJ, Portmann B, Edleston ALWF, Williams R. The value of clinical, biochemical, ultrasound and liver biopsy data in assessing patients with liver disease. *Liver*. 1983;3:315-326.
43. Theodossi A. The value of symptoms and signs in the assessment of jaundiced patients. *Clin Gastroenterol*. 1985;14:545-557.
44. Harding SR, Cowan DHC. The midclavicular line: a wandering landmark. *Can Med Assoc J*. 1987;136:921.